

EXAMINATION OF THE LYMPH NODES

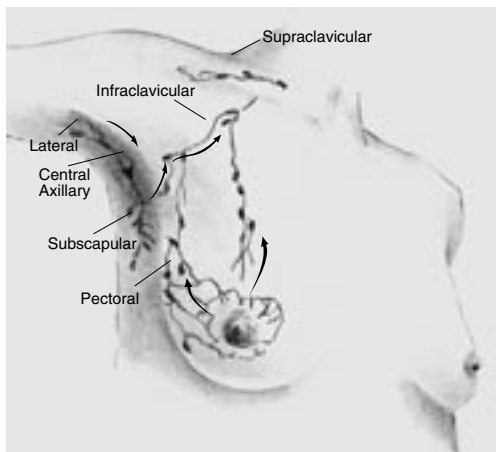


Figure 1

Lymph Drainage of the Breast (Figure 1)

Seventy-five percent of the lymphatic drainage from the breast is into the axillary nodes. Lymph from 3 groups of axillary nodes, the lateral, the subscapular and the pectoral, drain into the central nodes that are high in the axillae. These nodal groups are also referred to as **Level I** (low axilla), **Level II** (mid-axilla) and **Level III** (apical axilla), as described in surgical or pathology reports.

Positioning for the Exam

The patient should be in a seated position for both the clavicular and axillary exam to optimize deep palpation. Lying down with the hand over the head tenses the axilla. Before examining the patient, explain the rationale and what you are looking for.

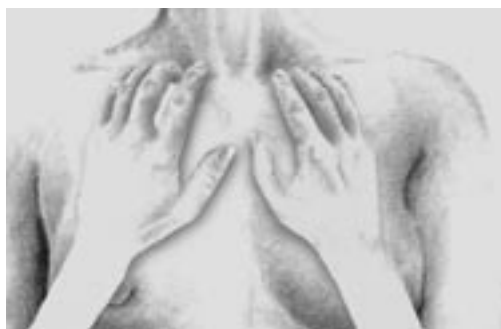

Figure 2

Palpation of the Supraclavicular and Infraclavicular Nodes (Figure 2)

- Using firm pressure in small circular movements, palpate above and below the clavicle.

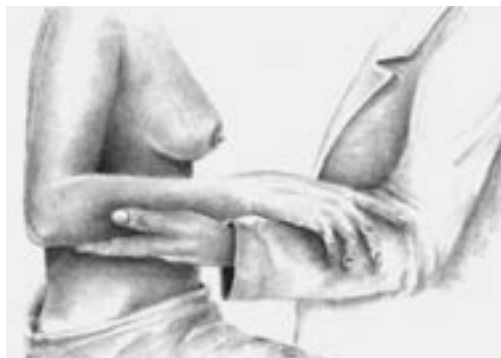
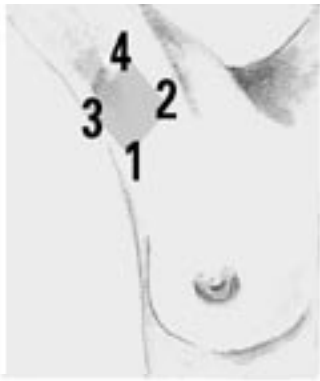
Figure 3

Palpating the Axillary Nodes (Figure 3)

- Instruct the patient to drop the shoulder and take a deep breath to facilitate relaxation.
- Support the patient's arm and elbow with the non-examining hand to maintain optimal relaxation.





**Palpation of the Axillary Nodes
(Figure 4a)**

Axillary nodes are palpated at deep pressure using a circular motion with the pads of the three middle fingers of the examining hand, in all four aspects of the axilla. Note that this pattern resembles a *diamond*.

Figure 4a

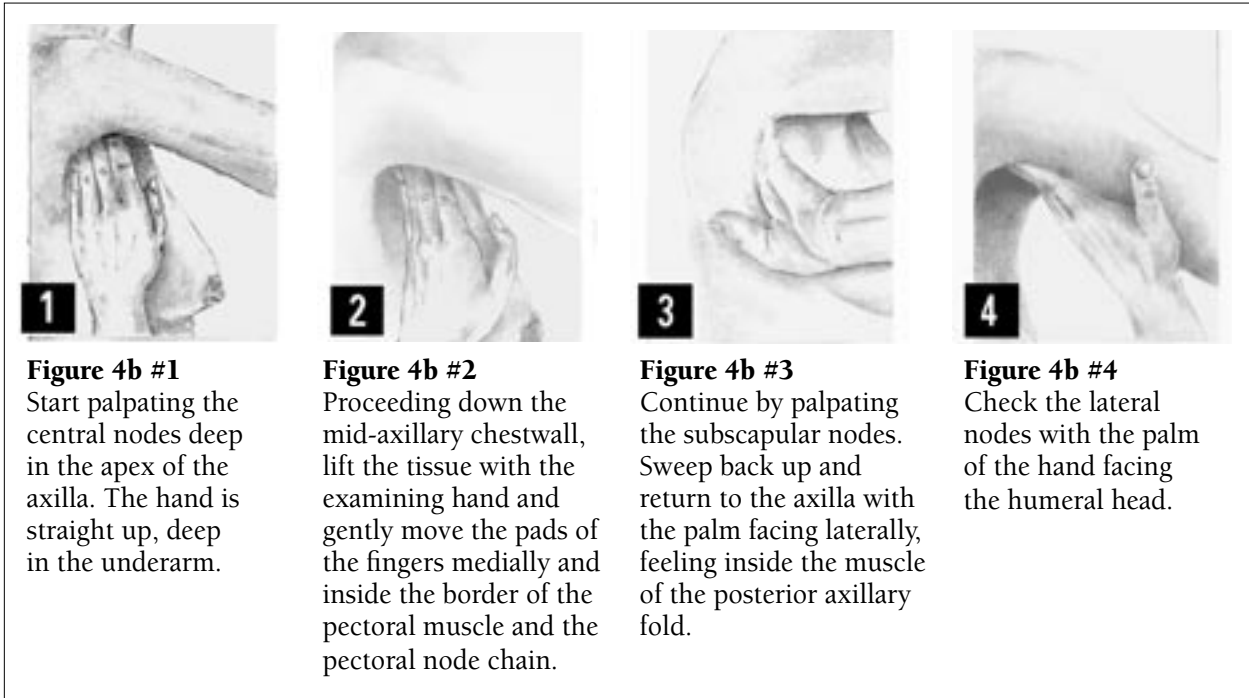


Figure 4b #1
Start palpating the central nodes deep in the apex of the axilla. The hand is straight up, deep in the underarm.

Figure 4b #2
Proceeding down the mid-axillary chestwall, lift the tissue with the examining hand and gently move the pads of the fingers medially and inside the border of the pectoral muscle and the pectoral node chain.

Figure 4b #3
Continue by palpating the subscapular nodes. Sweep back up and return to the axilla with the palm facing laterally, feeling inside the muscle of the posterior axillary fold.

Figure 4b #4
Check the lateral nodes with the palm of the hand facing the humeral head.

Figure 4b

Findings

Shotty nodes are usually small and less than 1cm, soft, mobile and of little clinical significance. Nodes that suggest inflammation or infection, or are fixed, matted or persistent, should be considered a suspicious finding. Note the size, shape, firmness and mobility. Appropriate follow-up may include mammography, ultrasound or other tests as indicated by history and clinical findings.

References

Bates, B. (1995). *Physical Examination and History Taking* 6th Edition. Philadelphia, JB Lippincott

Gray, Henry. (2000). *Gray's Anatomy In Chapter: Lymphatics of the Upper Extremity*, 15th Edition. New York, Barnes & Noble Publishers.

Harris, J; Lippman, M; Morrow, M & Hellman, S. (1996). *Diseases of the Breast*. In Chapter 1: Breast Development & Anatomy, Philadelphia, Lippincott-Raven

