Algorithm 2: New Palpable Mass

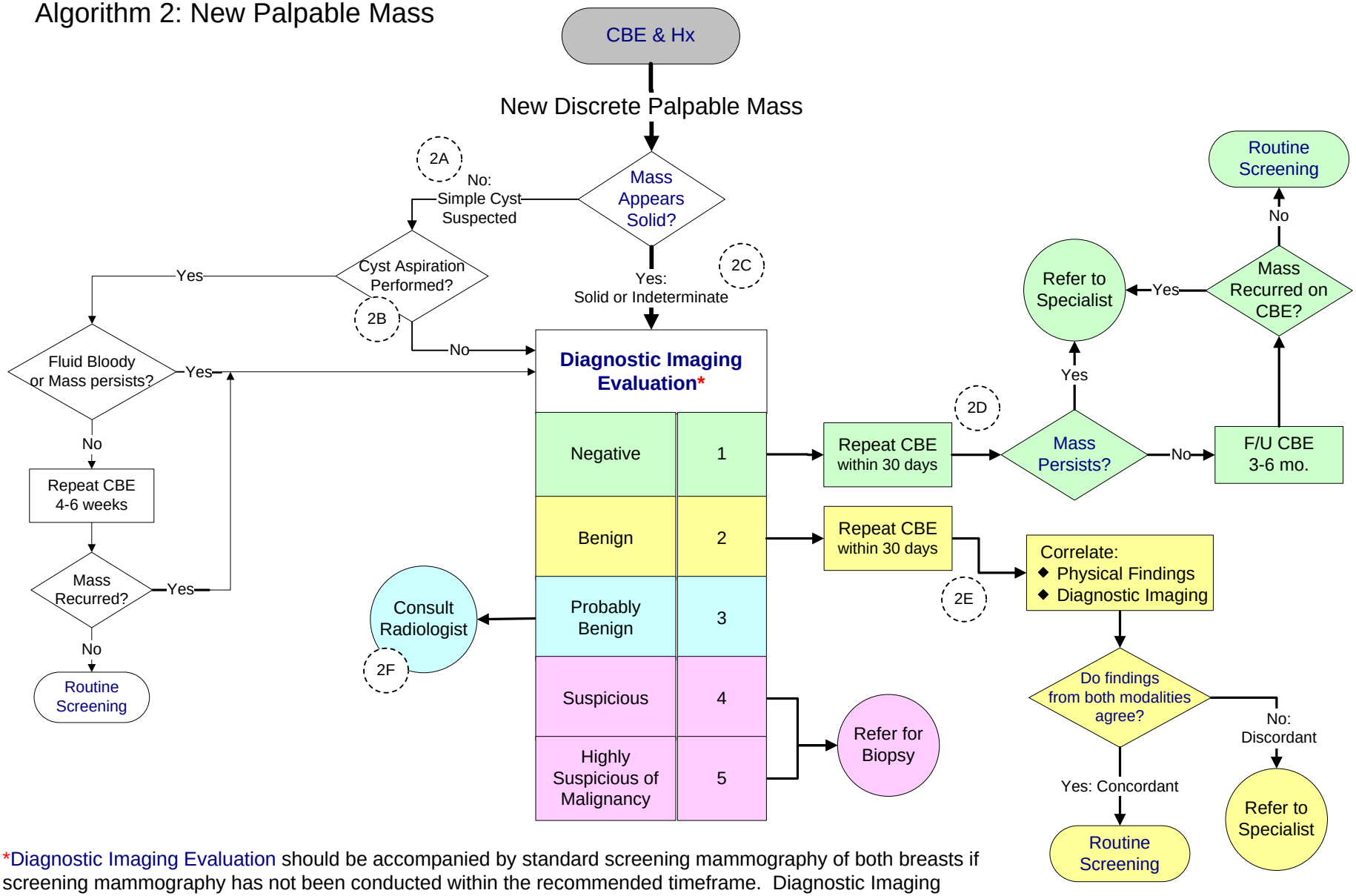

*Diagnostic Imaging Evaluation should be accompanied by standard screening mammography of both breasts if screening mammography has not been conducted within the recommended timeframe. Diagnostic Imaging Evaluation will often include diagnostic mammogram and breast ultrasound, but can also include any radiographic imaging procedure recommended by the radiologist. A final BI-RADS category will be assigned to the case based on the results of all diagnostic imaging procedures. Women should return to routine screening once the diagnostic and/or treatment cycle is completed.

California Department of Health Services, 2005

◈◈◈◈◈◈◈◈◈◈◈◈◈◈◈◈◈◈◈◈◈◈◈◈◈◈◈◈◈◈ FLOWCHART NOTES ◈◈◈◈◈◈◈◈◈◈◈◈◈◈◈◈◈◈◈◈◈◈◈◈◈◈◈◈◈◈

NOTE 2A: Upon detection of a palpable breast mass, the PCP may suspect a simple cyst. This diagnosis must be confirmed with ultrasound or fine needle aspiration/biopsy. A breast mass that completely resolves by needle aspiration of non-bloody fluid can be considered insignificant if there are no signs of recurrence four to six weeks post-aspiration (Pruthi, 2001). Ultrasonography depicts the fluid within cysts and can diagnose cysts with a diameter as small as 2-3 mm in small breasts. Ultrasound is less sensitive in large breasts due to the fatty breast tissue. Although multiple cysts commonly occur, a woman with breast cysts needs to be advised to seek medical advice whenever a new mass arises. Neither the clinician nor the woman can automatically assume that a new mass is "just another cyst." Non-palpable cysts detected by mammography and confirmed by ultrasound do not need to be aspirated unless they are symptomatic and cause pain. A cyst that recurs more than two times within four to six weeks, contains bloody fluid, or leaves a residual palpable mass post-aspiration demands a diagnostic imaging evaluation. In this situation, the radiologist should be informed that an aspiration was undertaken prior to the imaging procedure. Cysts with internal debris or thick material require further follow-up.

NOTE 2B: Clinician confidence level in performing cyst aspiration may vary. Proceed with diagnostic imaging evaluation (e.g., ultrasound) if routine aspiration is not offered in your practice.

NOTE 2C: A clinically suspicious mass may have one or more features consistent with cancer, such as firmness, irregularity, or solitary. Sometimes such masses are fixed and associated with skin retraction. Any asymmetrical finding should be cause for concern (Barton, 1999; Goodson, 1996). ***Patients with suspicious findings should be referred to a breast surgeon immediately.***

NOTE 2D: Patients with a new palpable mass and Negative (BI-RADS® category 1) diagnostic imaging evaluation result should at minimum have a repeat CBE within thirty days. The negative imaging result indicates that there were no radiographically identified lesions, but does not preclude existence of a non-radiographically evident lesion. The follow-up CBE will allow the PCP to determine whether the palpable mass is persistent. If the mass is not persistent, there should be another repeat CBE in 3-6 months. If this confirms that the mass is no longer present, the patient can then return to routine screening intervals. Patients with negative imaging, in whom the mass persists at a follow-up CBE, should be referred to a breast specialist for decisions regarding follow-up interval or need for biopsy.

NOTE 2E: Patients with a Benign finding (BI-RADS® category 2) on mammogram should have a repeat CBE within thirty days. This allows the practitioner to correlate the physical findings with the diagnostic imaging evaluation and assure that the finding is concordant. The imaging finding identifies the anticipatory physical finding as benign; if there is no correlation between the imaged mass and the palpable mass, the patient should be referred to a breast specialist for decisions regarding interval follow-up or tissue biopsy. Mammography should be performed using a radio-opaque marker on the skin over a palpable lesion to assist in determining if the palpable mass corresponds to the mammographically identified lesion. A discordant mammographic finding may represent a separate lesion, which may need further evaluation in addition to a work-up for the original palpable mass. Careful correlation of the physical exam and the diagnostic imaging evaluation is critical to assure appropriate and timely follow-up. If the imaging findings show a simple cyst, it can be aspirated during a follow-up CBE if required to alleviate discomfort.

NOTE 2F: The American College of Radiology does not recommend the assignment of a Probably Benign (BIRADS category 3) result as the final diagnostic imaging evaluation for a patient with a palpable mass. This may occur if the radiologist is unaware of the CBE findings. If the results of your CBE screening indicate a palpable mass and you receive a BIRADS category 3 final diagnostic imaging evaluation, contact the radiologist for further consultation.