
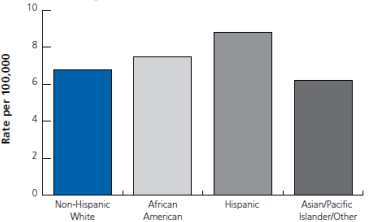
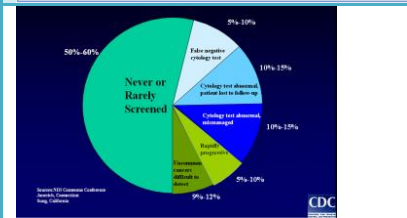


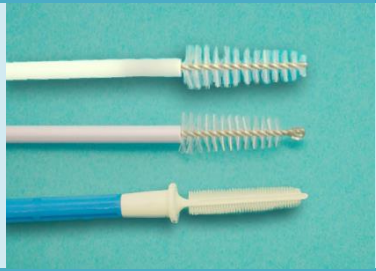
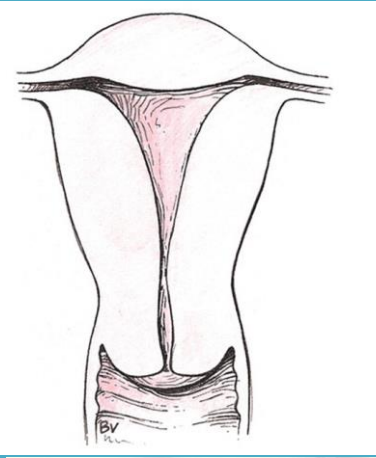
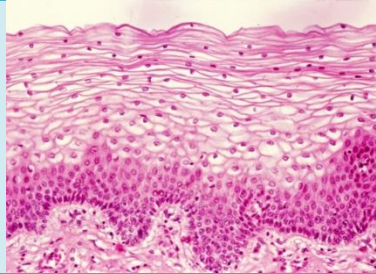
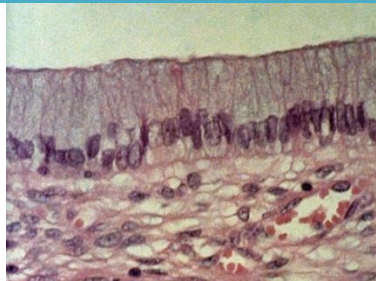



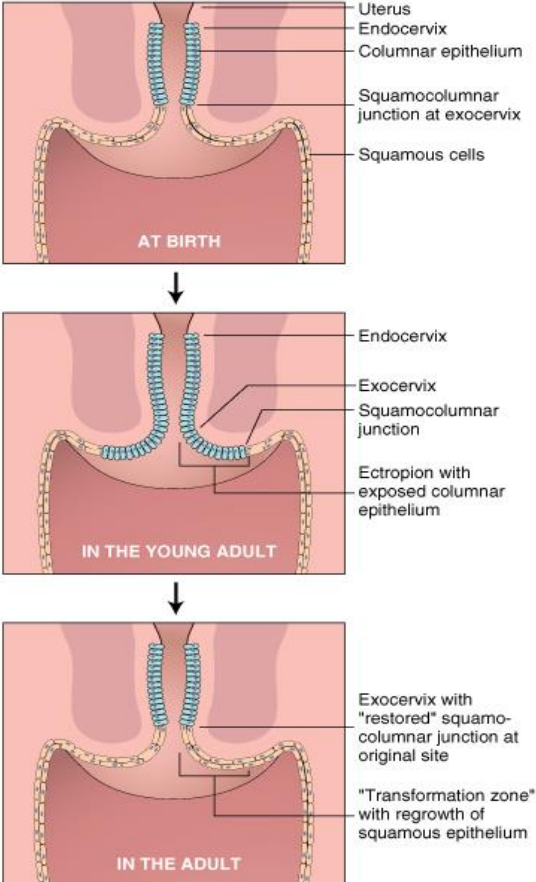
Cervical Cancer Screening & Diagnostic Follow-Up Web Module
Image Permission

Image	Image description	Source/permission
	ASCCP Algorithms	Reprinted from <i>Ihe Journal of Lower Genital Tract Disease</i> Volume 17, Number 5, with the permission of ASCCP @ American Society for Colposcopy and Cervical Pathology 2013. No copies of the algorithms may be made without the prior consent of ASCCP.
<p data-bbox="163 456 499 496">Figure 17. Invasive Cervical Cancer Incidence by Race/Ethnicity in California, 2011</p>  <p data-bbox="163 716 531 764">Note: Rates are age-adjusted to the 2000 US population. Source: California Cancer Registry, California Department of Public Health. Prepared by the California Department of Public Health, California Cancer Registry.</p>	Cervical cancer incidence	American Cancer Society California Department of Public Health California Cancer Registry. (2014). <i>California cancer facts and figures 2014</i> . Oakland, CA.
	Cervical cancer challenges	Image Adapted From: Lawson, H. W. (2001). <i>Cervical cancer: Opportunities and challenges for decreasing incidence and mortality [PowerPoint slides]</i> . Centers for Disease Control and Prevention.
	Cytology collection device-broom	Reprinted with permission from the <i>Institute for Public Health, San Diego State University Graduate School of Public Health</i>
	Cytology collection device-spatula	Reprinted with permission from the <i>Institute for Public Health, San Diego State University Graduate School of Public Health</i>



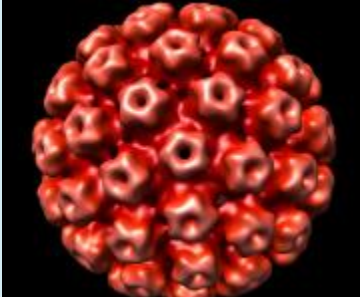

Cervical Cancer Screening & Diagnostic Follow-Up Web Module
Image Permission

Image	Image description	Image description	Source/permission
		Cytology collection device-brushes	Reprinted with permission from the <i>Institute for Public Health, San Diego State University Graduate School of Public Health</i>
		Uterus and cervix	<i>FOTOSEARCH, Waukesha, WI. Image purchased March 2011.</i>
		Stratified squamous epithelium	Biophoto Associates/Science Source. <i>Stratified Squamous Epithelium</i> . Image purchased March 2015.
		Columnar epithelium	Biophoto Associates/Science Source. <i>Endocervix, LM</i> . Image purchased March 2015.



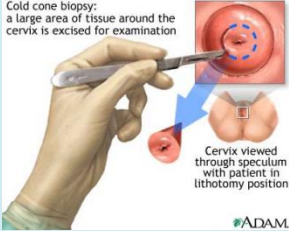
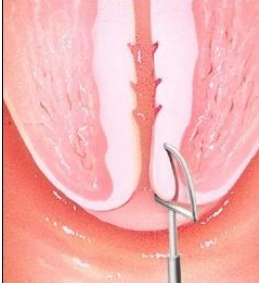
Cervical Cancer Screening & Diagnostic Follow-Up Web Module
Image Permission

Image	Image description	Source/permission
	<p>Cervix squamocolumnar junction</p>	<p>Apgar, B. S., Brotzman, G. L., & Spitzer, M. (2008). <i>Colposcopy: Principles and practice</i>. Copyright Elsevier. Image purchased July 2015.</p>
 <p>The diagram illustrates the transformation zone of the cervix at three stages:</p> <ul style="list-style-type: none"> AT BIRTH: Shows the uterus, endocervix, and columnar epithelium. The squamocolumnar junction is located at the exocervix, and the area is covered with squamous cells. IN THE YOUNG ADULT: Shows the endocervix and exocervix. The squamocolumnar junction has moved inward, and ectropion with exposed columnar epithelium is visible. IN THE ADULT: Shows the exocervix with a "restored" squamocolumnar junction at the original site. A "Transformation zone" with regrowth of squamous epithelium is indicated. <p>© Elsevier Ltd. Kumar et al: Basic Pathology 7E www.studentconsult.com</p>	<p>Transformation zone</p>	<p>Kumar, V., Abbas, A. K., & Aster, J. C. (2012). <i>Robbins basic pathology</i>. Copyright Elsevier. Image purchased July 2015.</p>

Cervical Cancer Screening & Diagnostic Follow-Up Web Module
Image Permission

Image	Image description	Source/permission
	Nabothian cyst	Reprinted with permission from Scott Moses, MD. Retrieved from http://www.fpnotebook.com/legacy/Gyn/Anatomy/CrvxAntmy.htm
	Genital warts	Centers for Disease Control and Prevention (2013). <i>Genital human papillomavirus (HPV)</i> [PowerPoint slides]. Reprinted with permission.
	HPV virus	Dr. Arthur Olson. <i>Scripps Research Institute</i> . Reprinted with permission.
	Curettes	Reprinted with permission from Mary Rubin.

Cervical Cancer Screening & Diagnostic Follow-Up Web Module
Image Permission

Image	Image description	Source/permission
	Colposcopy	Feltmate, CM, & Feldman, SF, Colposcopy. In: UpToDate, Post, TW & Goff, B (Eds), UpToDate, Waltham, MA, 2016.
	Cervical forceps	Reprinted with permission from <i>CareFusion</i> . Retrieved from https://catalog.carefusion.com/vmueller/
 <p>Cold cone biopsy: a large area of tissue around the cervix is excised for examination</p> <p>Cervix viewed through speculum with patient in lithotomy position</p> <p>ADAM</p>	Cone biopsy	Reprinted with permission from <i>A.D.A.M Images</i> . Image purchased May 2011.
	LEEP	Reprinted with permission from The StayWell Company, LLC. The Staywell Company, LLC 780 Township Line Road Yardley, PA 19067 267-685-2500